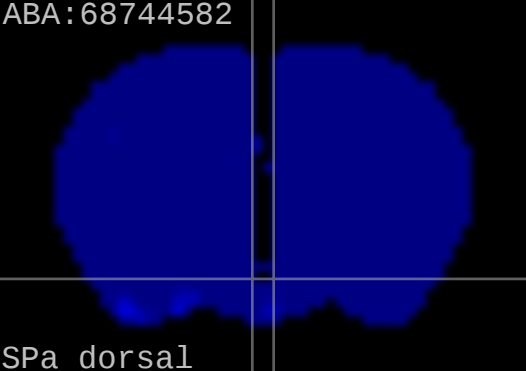


ABA:68162263

SPa dorsal

The image displays four quadrants of a brain scan, likely a coronal slice, with a blue highlighted region. The top-left quadrant is labeled 'ABA:68162263' and the bottom-left quadrant is labeled 'SPa dorsal'. The blue region is centered in the dorsal part of the brain, spanning across the vertical midline. The rest of the brain tissue is shown in grayscale, and the background is black.