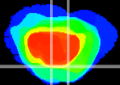
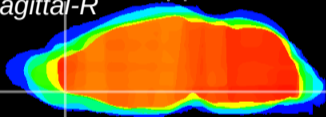


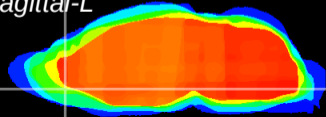
Coronal



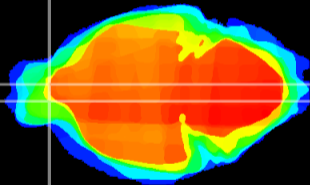
Sagittal-R



Sagittal-L



ViBrism: CX06893
Horizontal



OB posterior