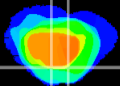
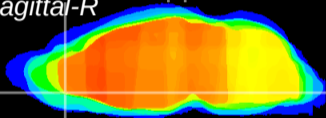


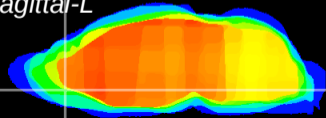
Coronal



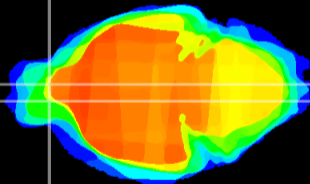
Sagittal-R



Sagittal-L



ViBrism: CX09181  
Horizontal



OB posterior