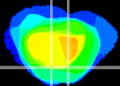
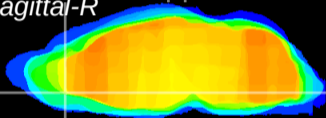


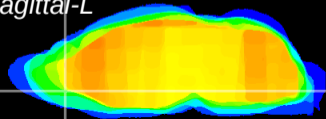
Coronal



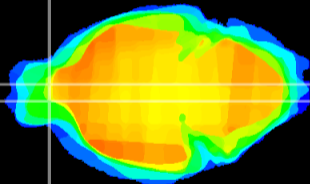
Sagittal-R



Sagittal-L



ViBrism: CX10739
Horizontal



OB posterior