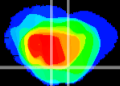
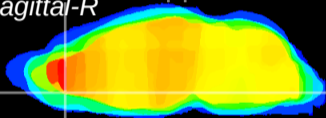


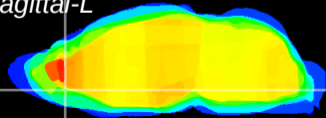
Coronal



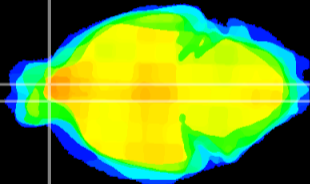
Sagittal-R



Sagittal-L



ViBrism: CX12162  
Horizontal



OB posterior