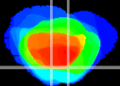




Coronal



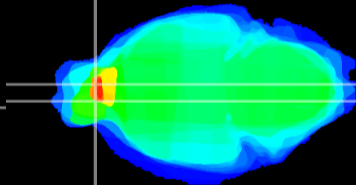
Sagittal-R



Sagittal-L



ViBrism: CX16454  
Horizontal



OB posterior