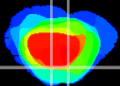
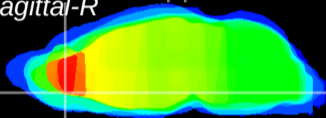


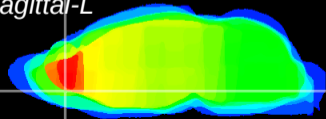
Coronal



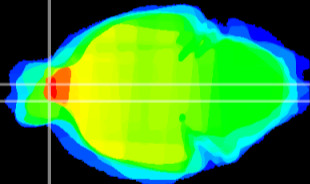
Sagittal-R



Sagittal-L



ViBrism: CX20888
Horizontal



OB posterior