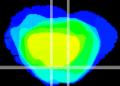
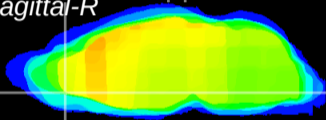


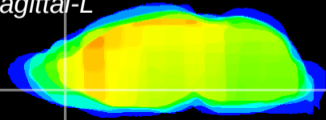
Coronal



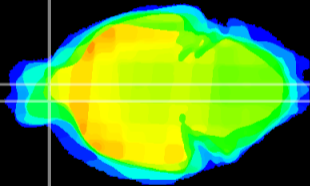
Sagittal-R



Sagittal-L



ViBrism: CX21004
Horizontal



OB posterior