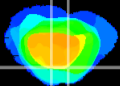
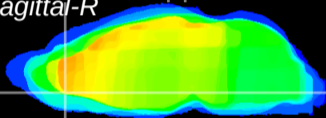


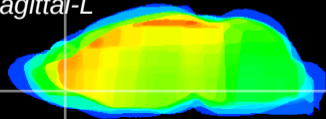
Coronal



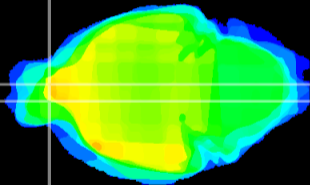
Sagittal-R



Sagittal-L



ViBrism: CX21897
Horizontal



OB posterior